



## From Editor's Desk

**Dr. Ajay Shankar Kar**  
Chief Consultant Ophthalmologist  
Cornea and Refractive Surgeon  
SevenHills Hospital, Visakhapatnam

It gives me immense pleasure to bring you the Volume 5 issue of SevenHills Health Byte.

In this issue we are dealing with two complicated cases and their management from department of paediatrics and plastic surgery. The first case is a case report of Systemic Lupus Erythematosus (SLE) child who was diagnosed and treated at Seven Hills hospital and is doing well. The second case is a rare complicated surgery of toe to thumb transfer managed and treated in department of plastic surgery, where the patient got a new thumb after injury.

SevenHills Hospital has treated all its patients' with empathy, sympathy beyond holistic approach to keep its tradition.

## SYSTEMIC LUPUS ERYTHEMATOSUS (SLE)

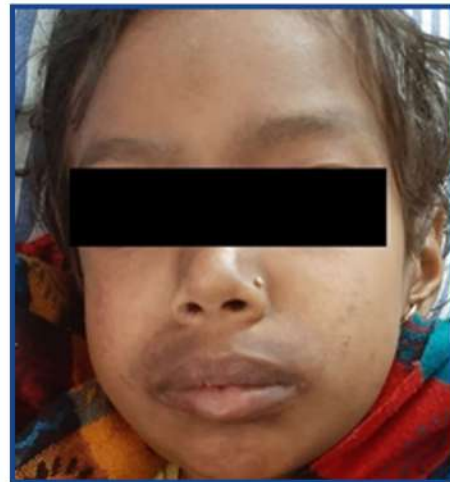### INTRODUCTION

The reported prevalence of SLE in children and adolescents (1-6/1, 00,000) is lower than in adults. SLE.

It predominantly affects females. A hallmark of SLE is the generation of auto antibodies directed against self-antigens particularly nucleic acids.

### CASE REPORT

13-year-old female (Figure 1), adolescent presented with complaints of weight loss, anasarca, joint pains and intermittent fever for 1 year.



**Figure 1**

**O/E:** Discoid rash, oral ulcers, non-scarring alopecia.

### INVESTIGATION

Nephrotic range proteinuria, hypoalbuminemia, raised CRP, raised ESR.

ANA profile was highly suggestive of SLE.

Renal Biopsy: shows features of a combined class 5- Membranous lupus Nephritis and class 4- diffuse lupus nephritis.

## TREATMENT

Targeting multiple aspects of the immune response could be more effective than single agent therapy.

Combination of Calcineurin inhibitors, MMF and corticosteroids showed good renal outcome in recent clinical trials.

Given lifelong nature of SLE, optimal care of children and adolescents with this disease also involves preventive practices.

For all patients, sunscreen and avoidance of prolonged direct sun exposures and other UV light may help control disease and should be reinforced at every visit with the patient.

Routine immunization is recommended particularly pneumococcal and annual influenza vaccinations.

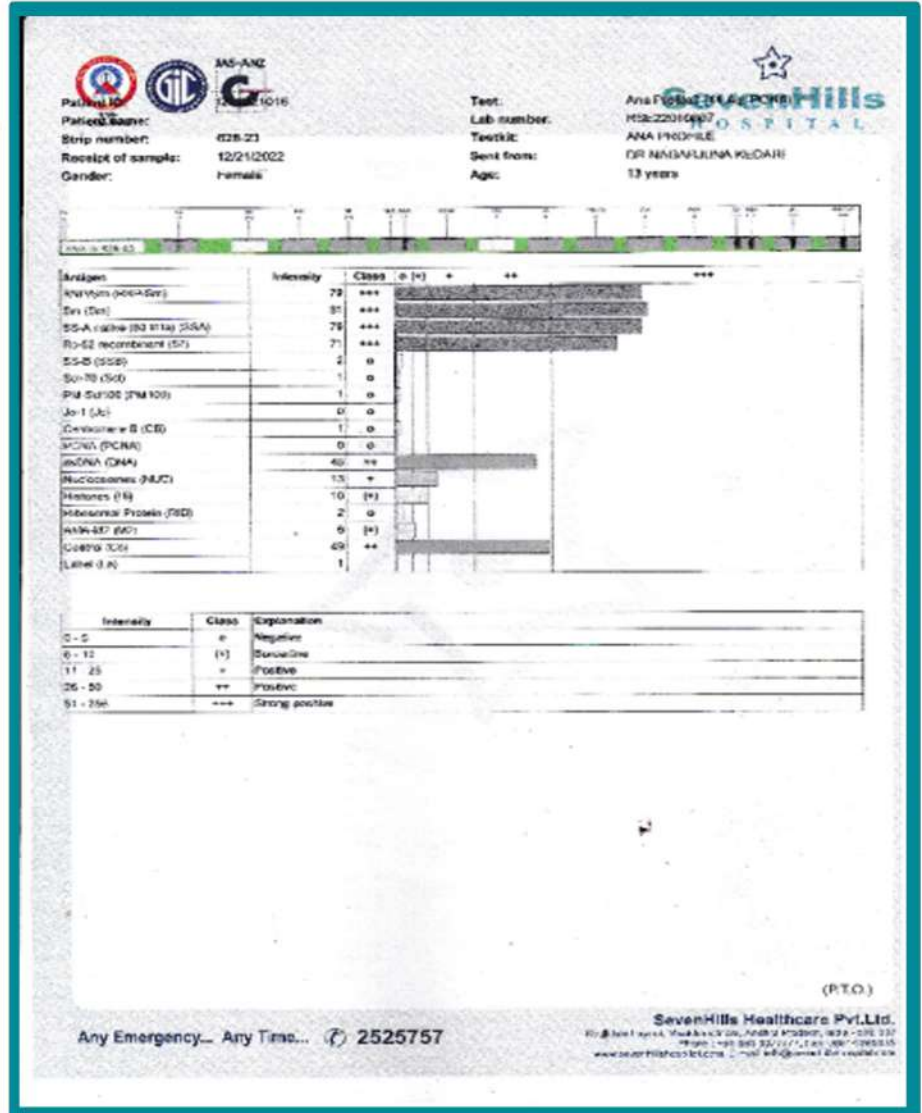


Figure 2



**Dr.K.Nagarjuna**

DNB(Ped), MRCPCH(UK), FACI, MNAMS,  
M.Sc (Psychology)

Consultant Paediatrician & Neonatologist

### Specialised In:

1. Level III NICU Care, PICU Care
2. Paediatric Allergy & Asthma
3. Immunological Problems
4. Childhood Behaviour Problems  
- Autism, ADHD
5. Skin Prick Test
6. Preterm Follow Up



## RARE SURGERY PERFORMED AT SEVENHILLS HOSPITAL BY TEAM PLASTIC SURGERY

A 38 year old man who works as a linesman at APSEB sustained an unfortunate accident a year back when he was working on a transformer which was accidentally switched on by a co-worker. He was brought to the emergency department of SevenHills hospital with approximately 45% deep burns with hypotension and myoglobinuria. All burns were deep 3rd degree burns and he also had compartment syndrome of the right upper extremity and completely charred left index finger and thumb. Needless to say, this patient would need prolonged care with extensive reconstructions and hence we formulated the goals of management.

### Goal 1:

The first priority was of course salvage of life.

### Goal 2:

Early cover of all burn wounds

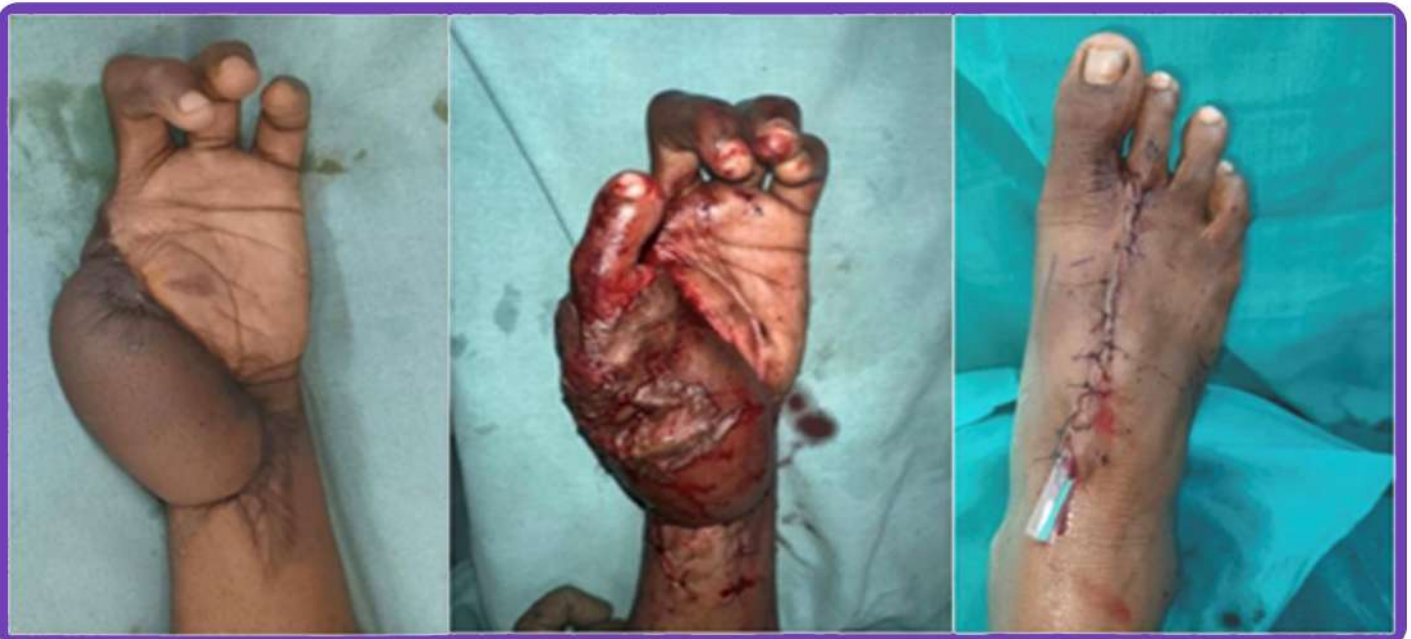### Goal 3:

Independent functions in at least one hand and if possible both hands, considering that he had severe burns of both upper extremities.

He was promptly resuscitated in the ICU and after stabilising him, emergency fasciotomy was done to release the tight compartments of his right forearm. Gradually he recovered from the initial shock and the myoglobinuria cleared. However, despite early decompression, the right hand became avascular and had to be amputated but early fasciotomy helped avoid a higher amputation as we were able to give him a functional elbow.

In the next stage, the charred thumb and index fingers of his left hand were amputated and a groin flap was done to cover the raw area to form a foundation for some form of thumb reconstruction in the future. So by the time he was discharged 1 month later, we were able to fulfil the first 2 goals of our management.

Now we had to face the bigger challenge of the 3rd goal. So, first a myoelectric prosthesis was customized for his right hand in which the electrodes transmitted the muscle contraction of the forearm to move the prosthetic hand (which was possible because the elbow had been salvaged). However he still had to depend on his wife for his basic day to day activities and he even needed help to wear the prosthesis.





So we needed to do something for his left hand. He had 3 fingers in his left hand and if we were able to give him a thumb, that hand would become functional. Hence we did a complex microsurgical procedure "toe to thumb transfer" on his left hand on 15th December 2022 exactly a year after his unfortunate accident. (Figure -1) The second toe of his right foot was successfully transplanted to his left hand. The surgery took nearly 11 hours wherein the 2nd toe of his right foot was painstakingly dissected on its blood supply and transferred to the hand. Initially, skeletal stabilisation was done with a 6 holed mini plate and screws. Once the bones were fixed, all the other structures were anastomosed to their counterparts in the hand. The digital vessels, digital nerves, and extensor and flexor tendons of the toe were carefully anastomosed to the radial vessels, palmar digital nerves and extensor and flexor tendons of the thumb under the microscope till there was good blood flow through the new thumb. He started walking within 4 days and has now started dedicated physiotherapy to teach his toe to function like a thumb. As humans, what sets us apart is our prehensile function. The thumb enables us to not only grasp big objects but also do fine intricate works like writing and painting. It performs 50% of the hand function and in its absence the hand is almost useless. It is no wonder then, that it is called the "King of Digits"!

The story of Dronacharya asking for Eklavya's thumb as Guru Dakshina so that he would not surpass Arjuna is common knowledge!

Of all the methods of thumb reconstruction, toe transfer is the most superior because the toe resembles the thumb in structure and function and most importantly it is sensate.

This is the first surgery of its kind to have been performed in Andhra Pradesh and is undoubtedly well worth the time, technical skill and infrastructure required for it. Removal of the second toe also does not affect how the person walks, at the same time restoring critical function of the hand. This surgery is a boon for individuals who may have lost their thumbs accidentally or in children who are born with deformed thumbs. This surgery will go a long way in rehabilitating the patient not only physically but also emotionally and psychologically and his entire family is extremely grateful to Seven Hills Hospital for the treatment offered to him. This case underlines the importance of multidisciplinary approach in the treatment of complicated cases such as these and formulation of a care plan early on so that the final outcome is favourable.



## Dr. Anjali Saple

M.S., DNB (Gen. Surgery),  
DNB (Plastic Surgery), MNAMS  
Consultant Cosmetic, Plastic &  
Microvascular Surgeon

## SPECIALISED IN

### Cosmetic Surgeries:

Rhinoplasty, Breast Surgeries, Abdominoplasty & Liposuction.

### Reconstructive Surgeries:

Brachial Plexus Surgery, Complex Trauma & Onco-reconstruction.



Waltair Main Road, Ram Nagar, Visakhapatnam - 53002, AP  
www.sevenhillshospital.com, Ph: 0891-6677777, 7996987070